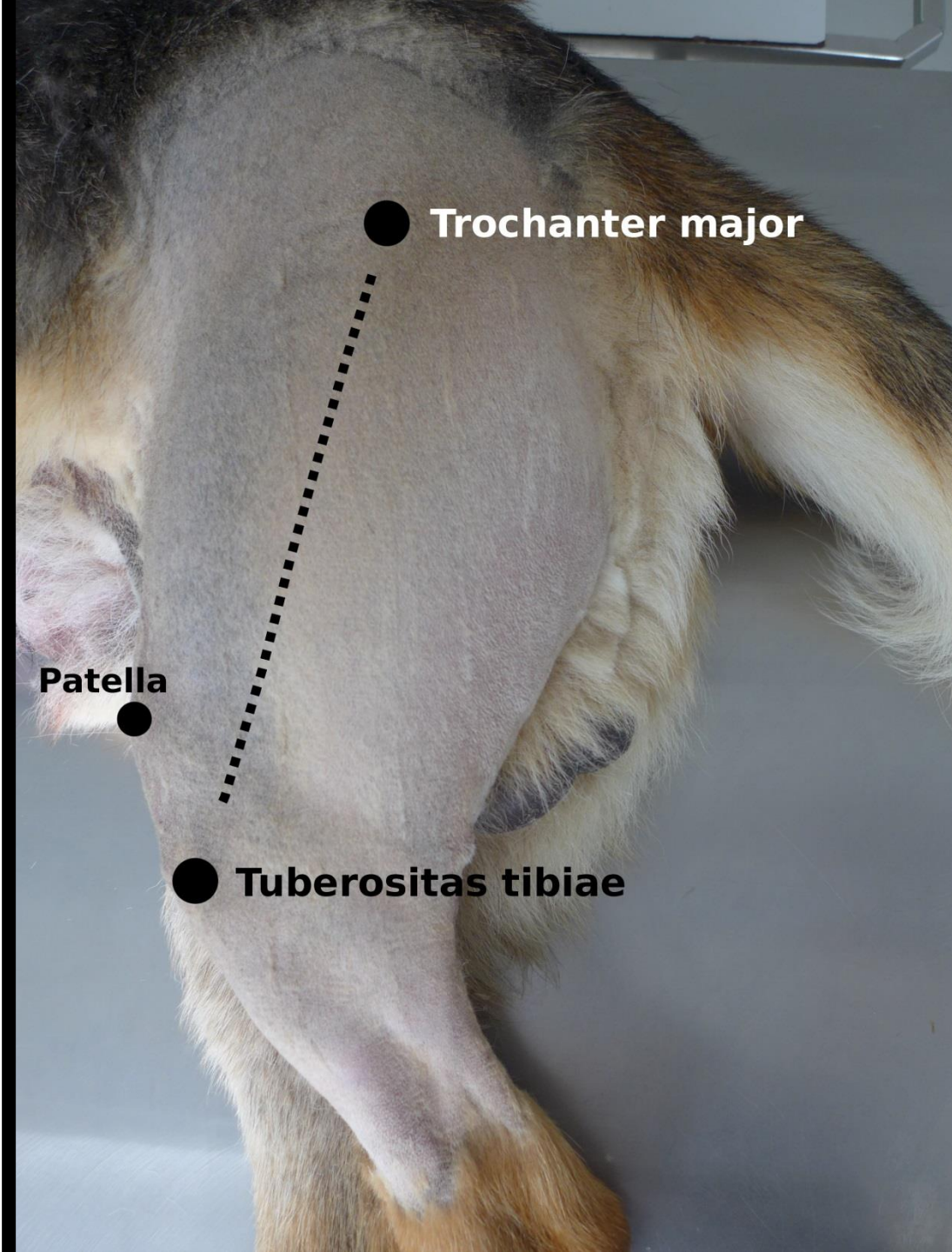


Chirurgické přístupy ke kostem

Femur – laterální přístup



● Trochanter major

● Patella

● Tuberositas tibiae

***M. tensor
fasciae latae***

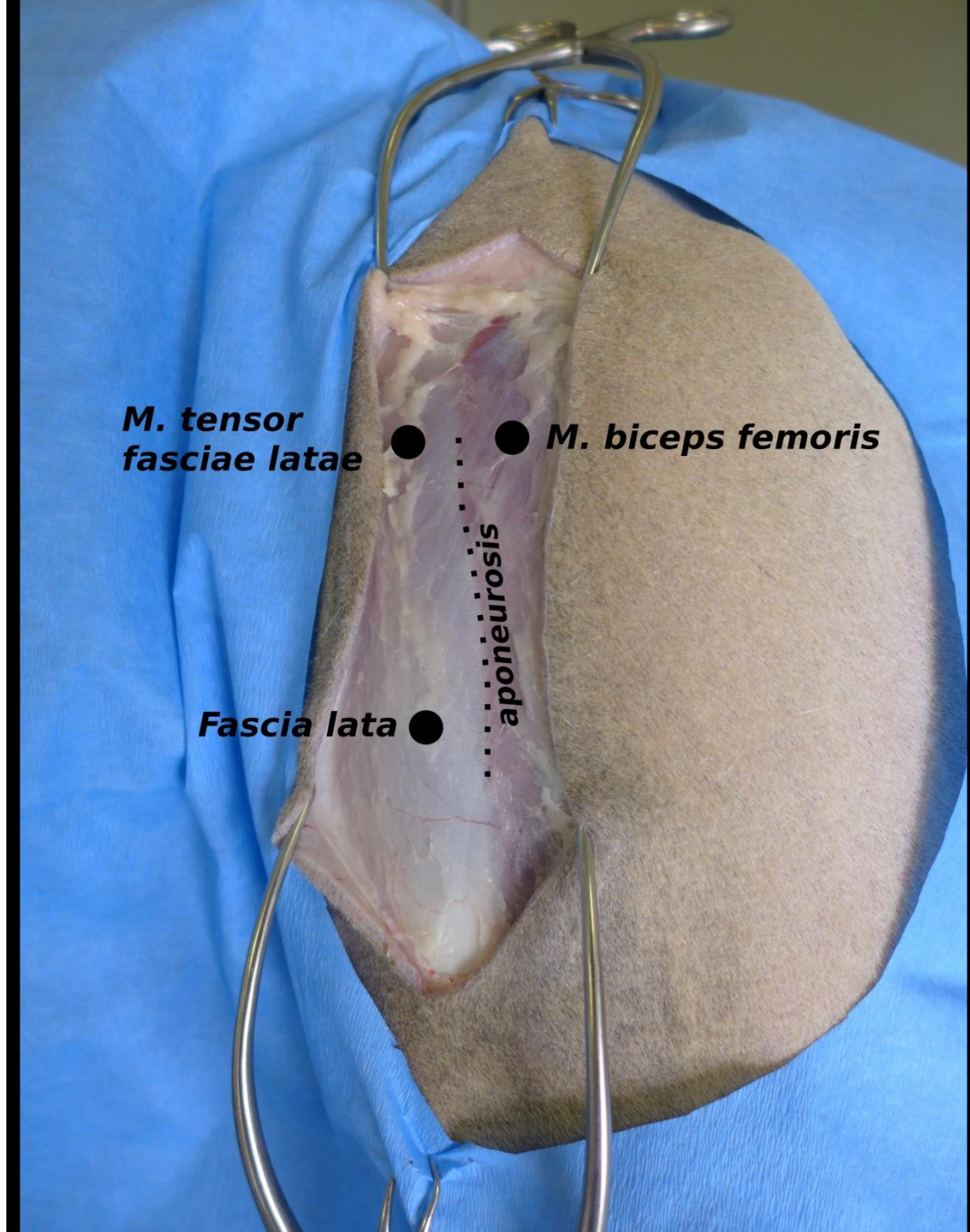


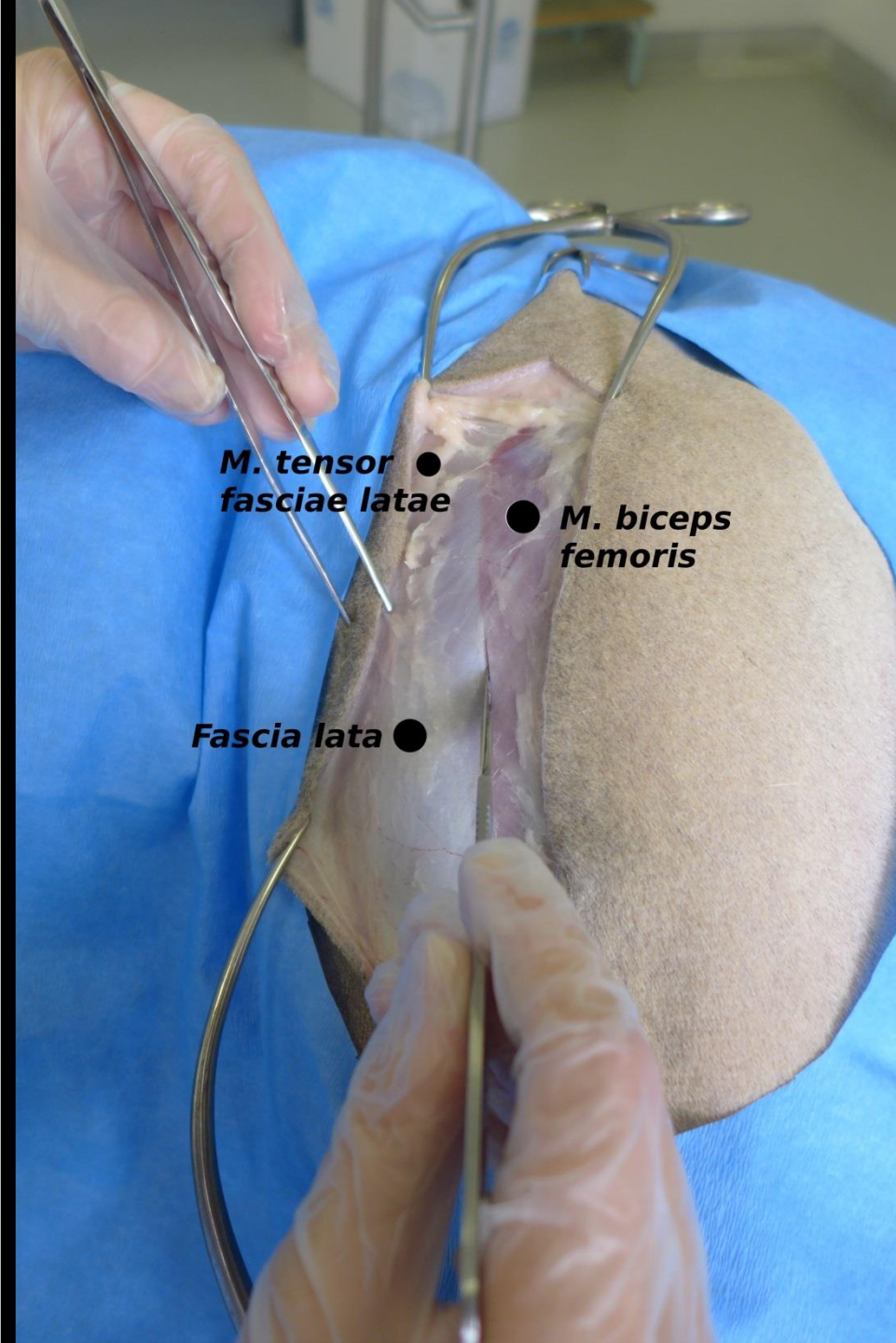
aponeurosis



M. biceps femoris

Fascia lata





***M. tensor
fasciae latae*** ●

● ***M. biceps
femoris***

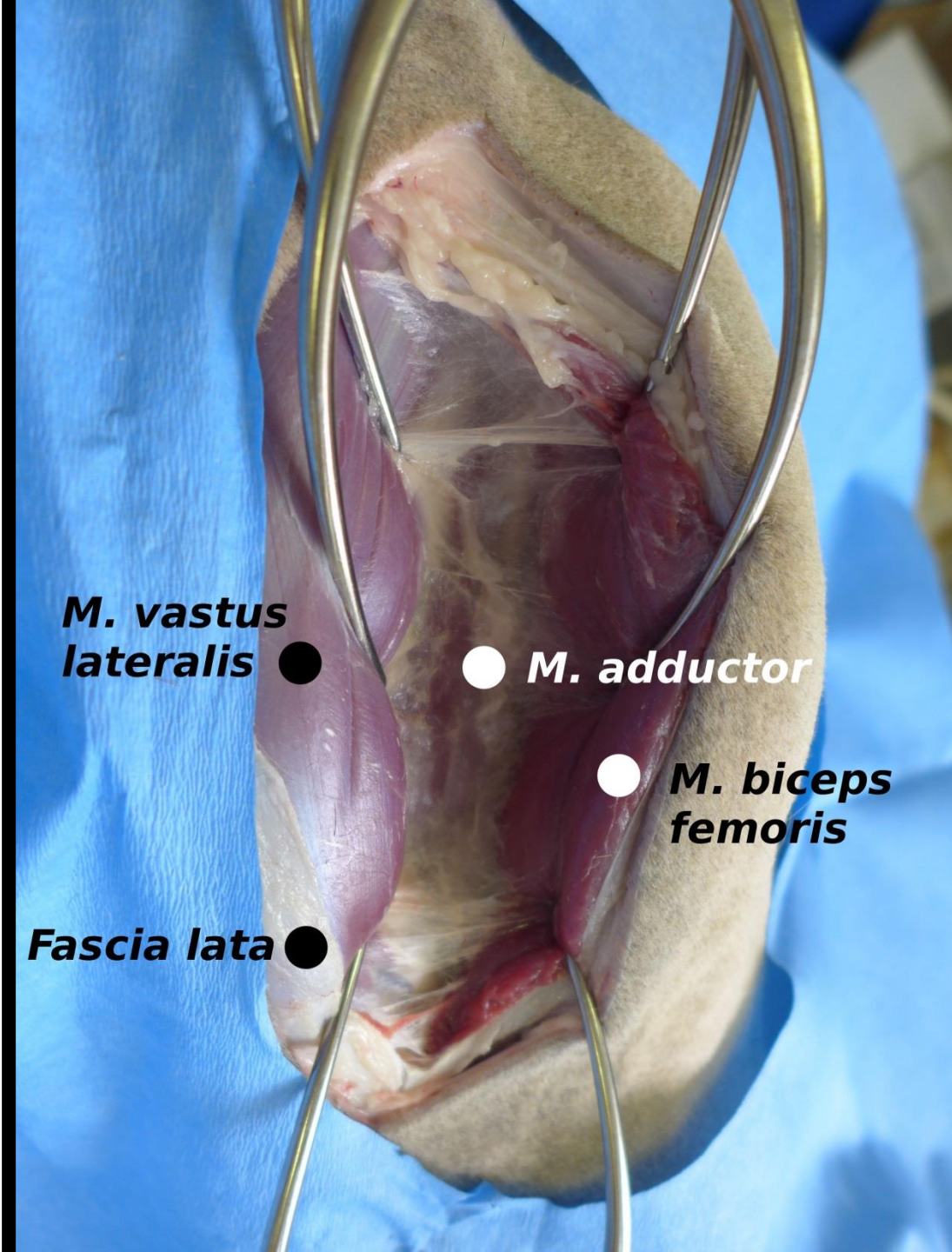
Fascia lata ●

M. vastus lateralis ●

● ***Cutis***

● ***M. biceps femoris***

Fascia lata ●

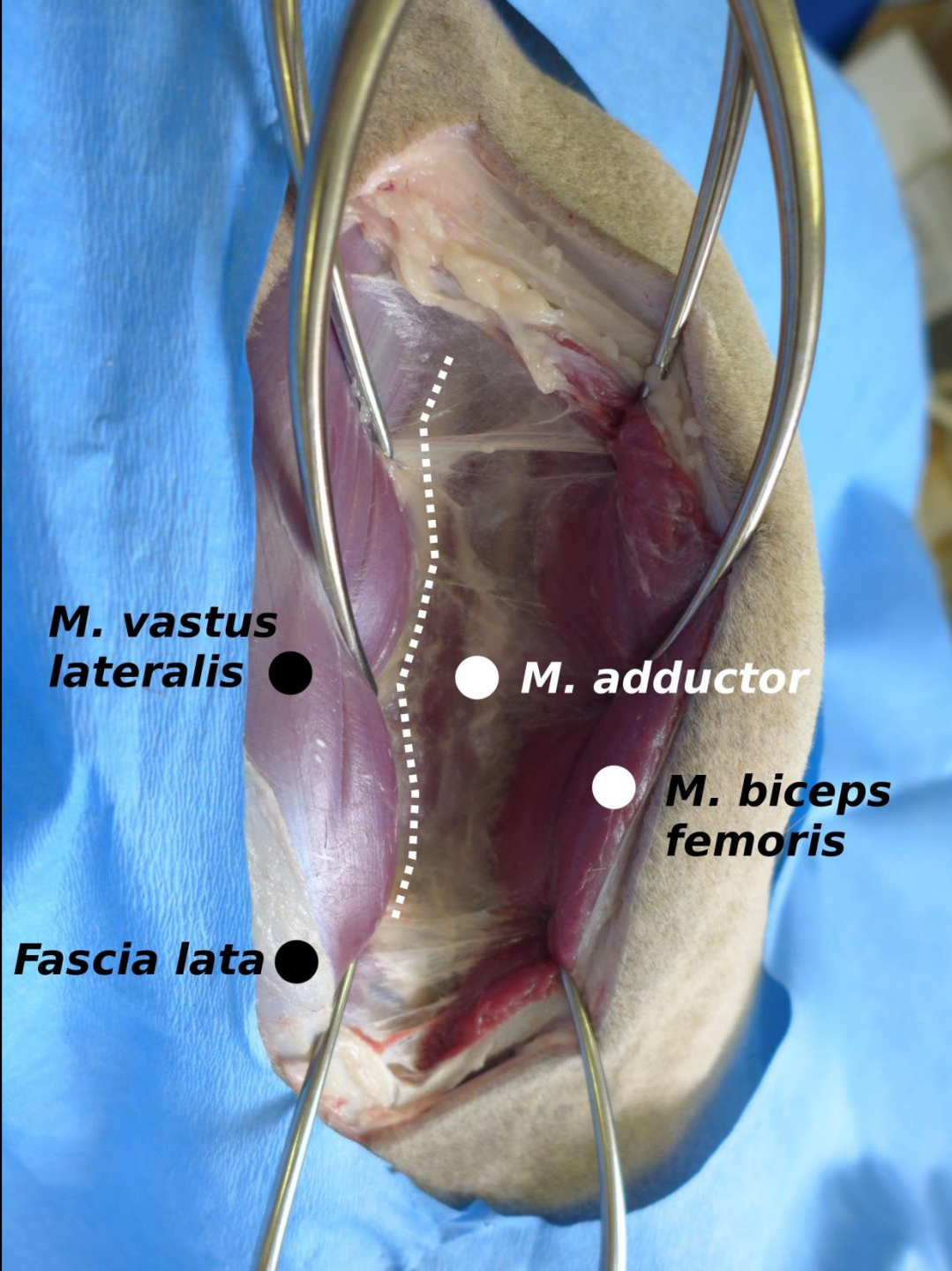


***M. vastus
lateralis*** ●

● ***M. adductor***

● ***M. biceps
femoris***

Fascia lata ●

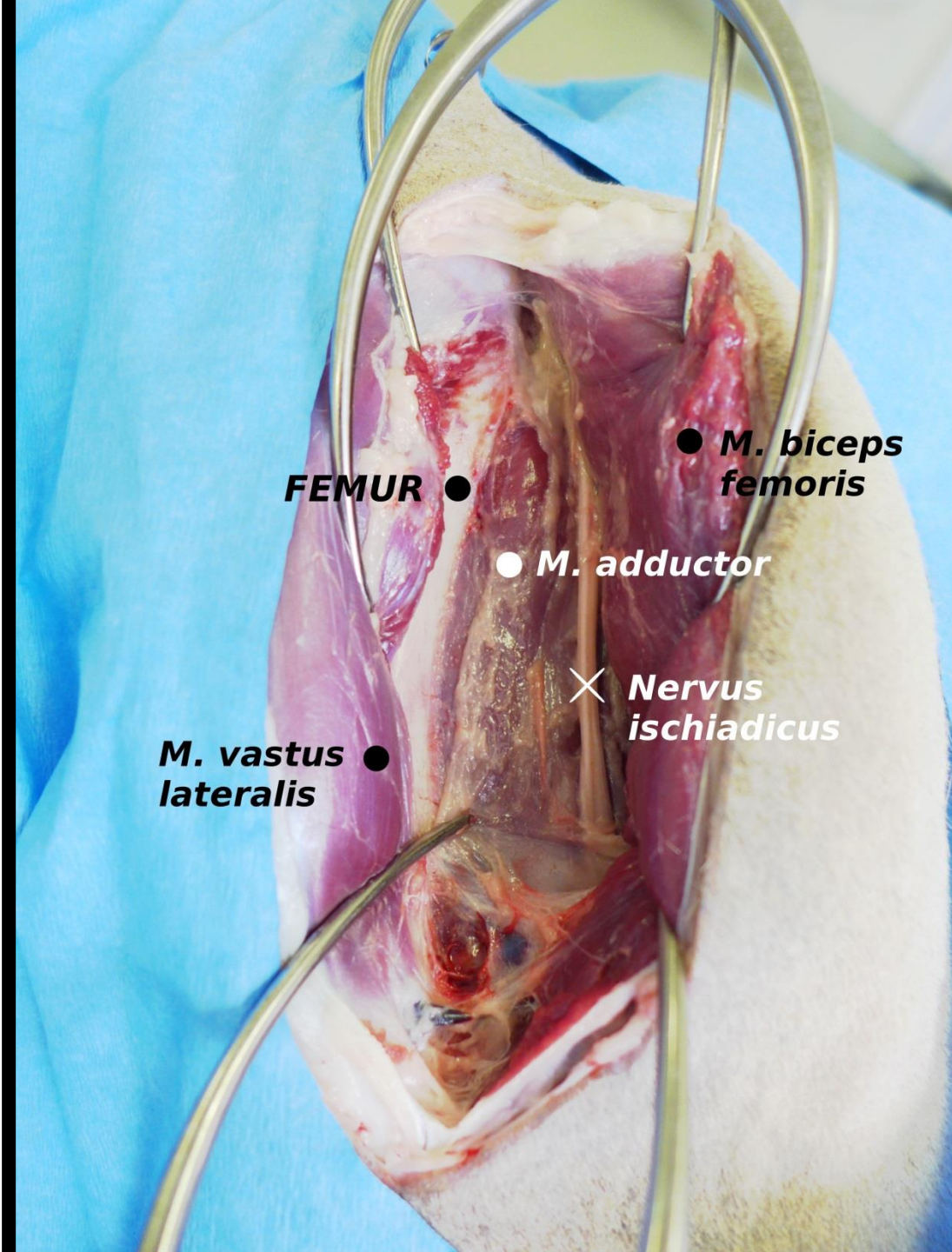


***M. vastus
lateralis*** ●

● ***M. adductor***

● ***M. biceps
femoris***

Fascia lata ●



FEMUR ●

● **M. biceps femoris**

● **M. adductor**

× **Nervus ischiadicus**

● **M. vastus lateralis**

