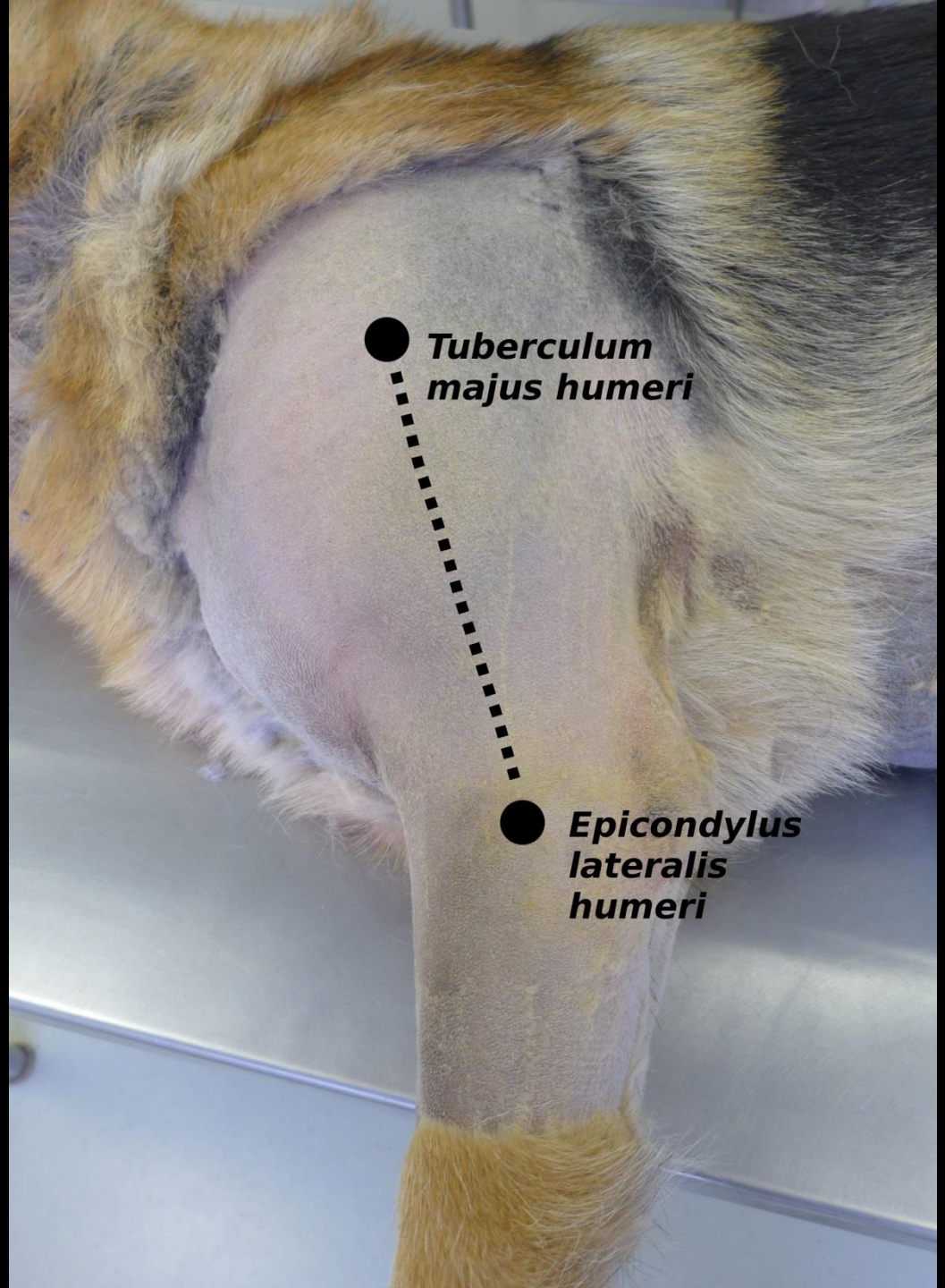


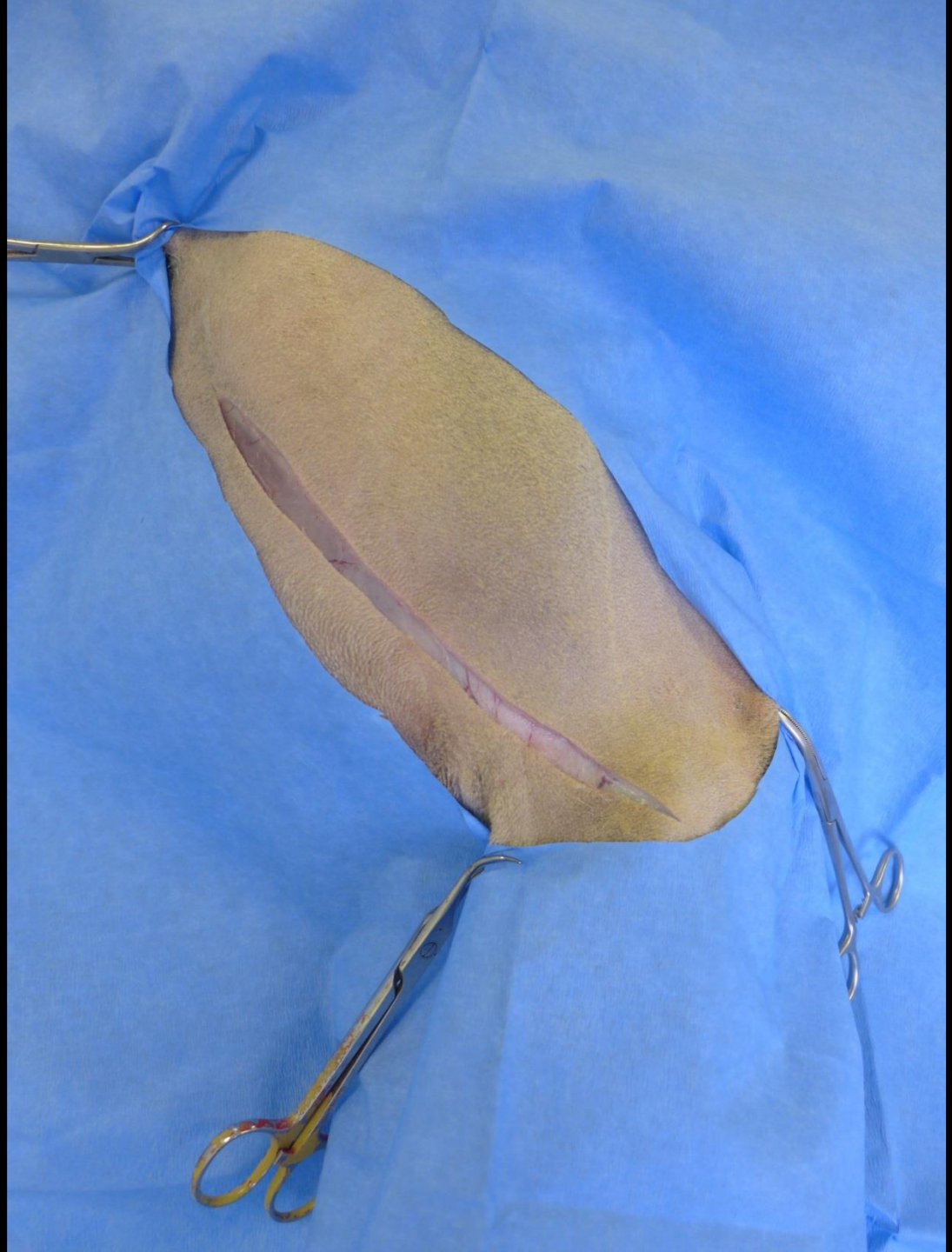
Chirurgické přístupy ke kostem

Humerus – kraniolaterální přístup



● ***Tuberculum
majus humeri***

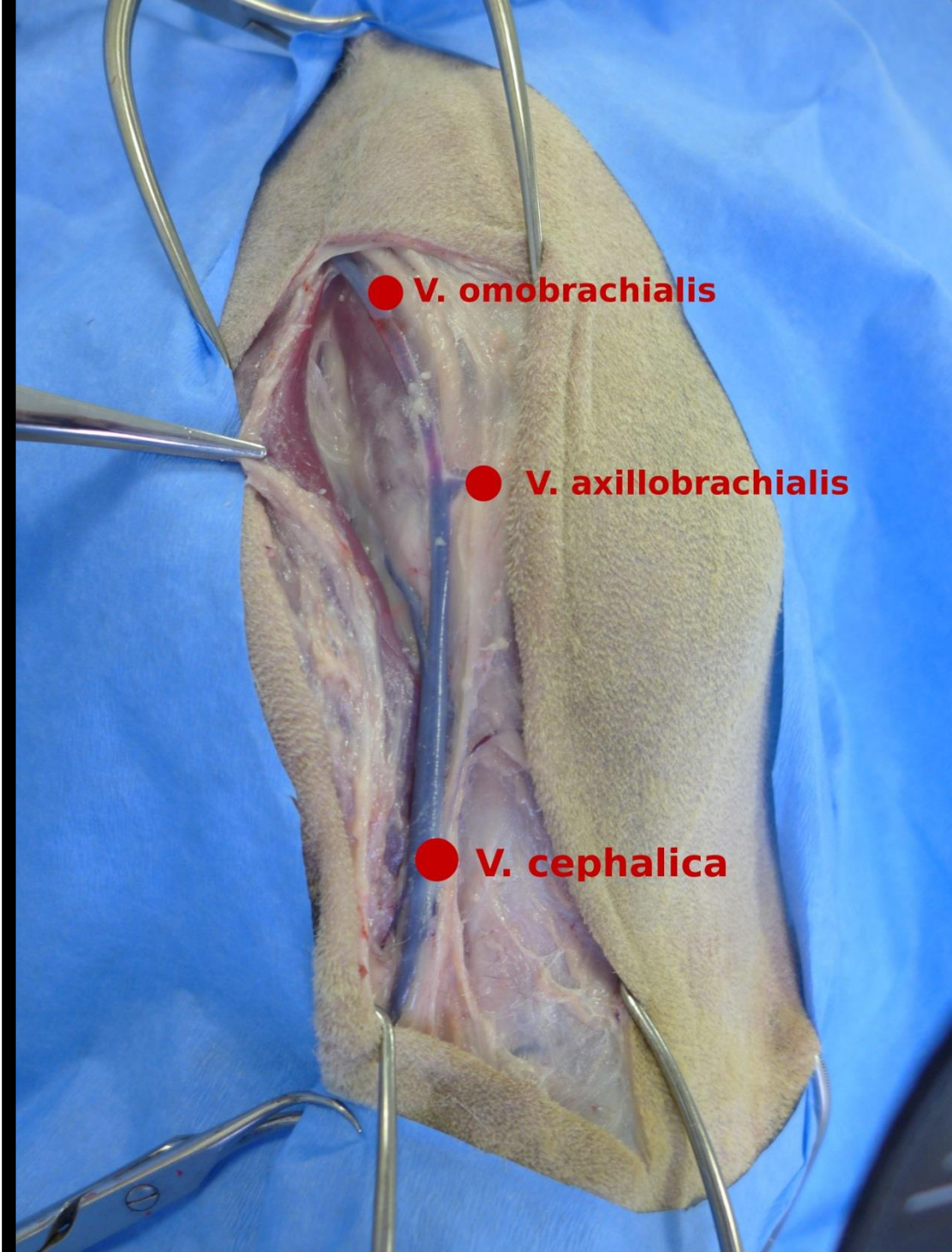
● ***Epicondylus
lateralis
humeri***





● **M. brachiocephalicus**

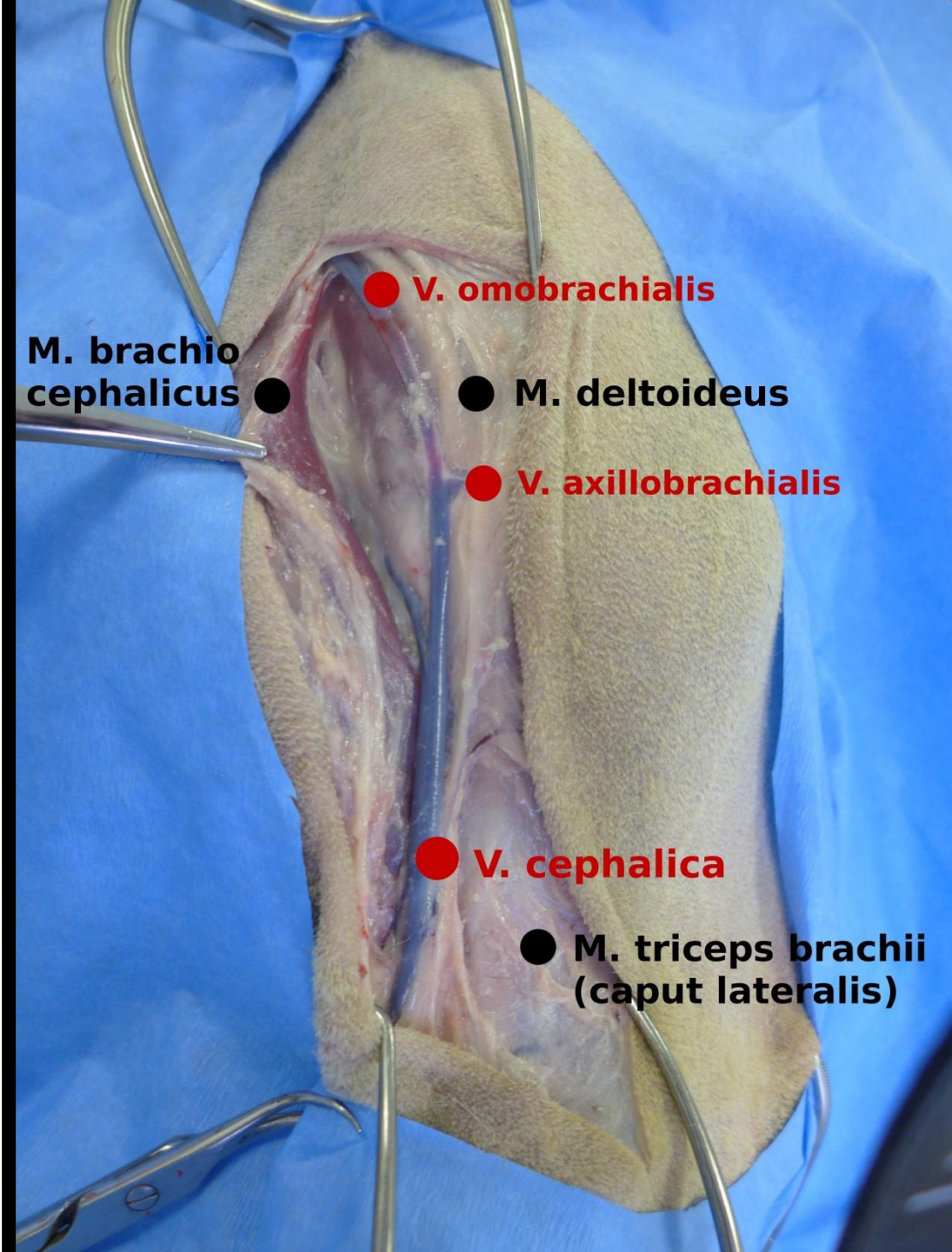
● **V. cephalica**



● **V. omo-brachialis**

● **V. axillo-brachialis**

● **V. cephalica**



● V. omobrachialis

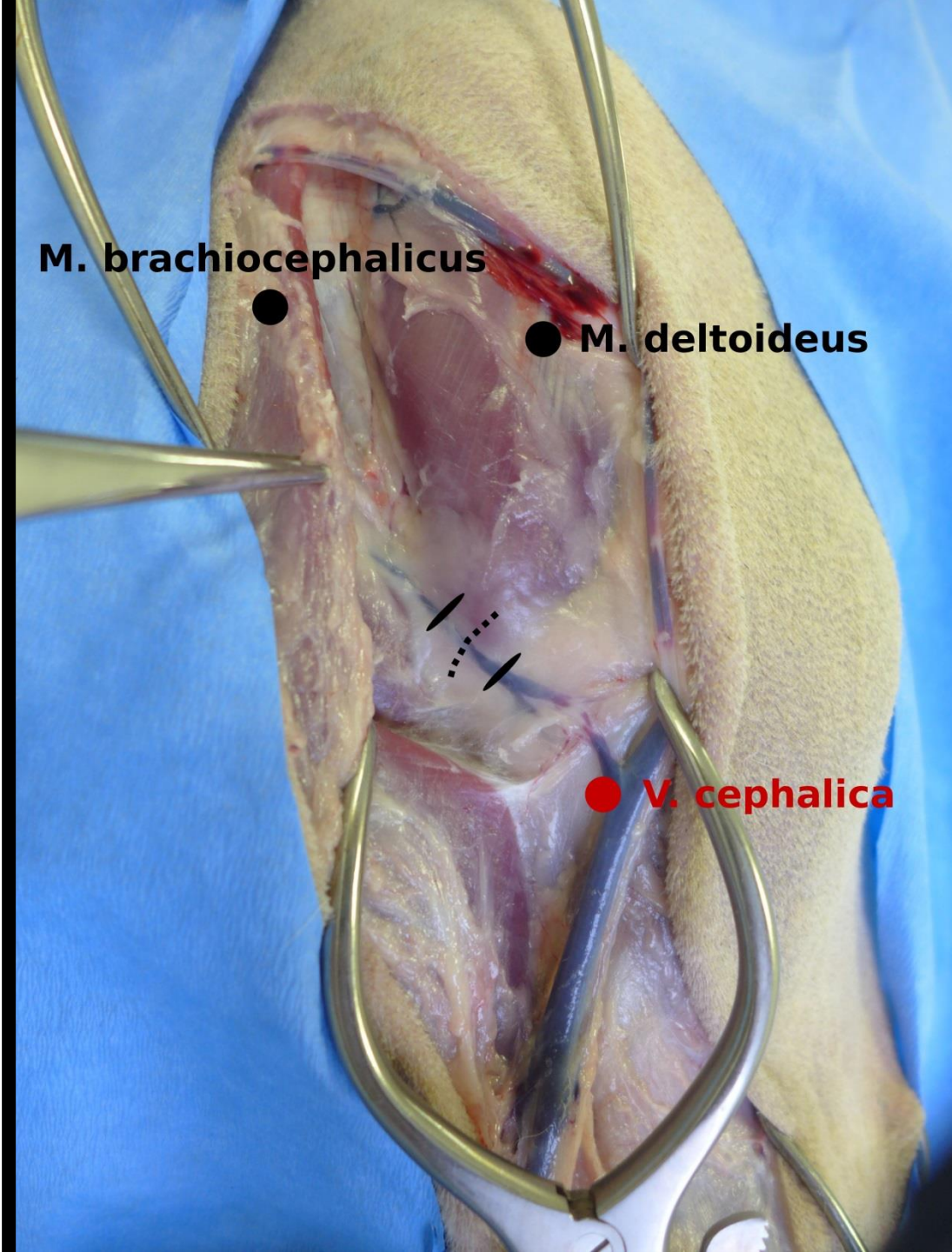
M. brachiocephalicus ●

● M. deltoideus

● V. axillobrachialis

● V. cephalica

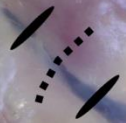
● M. triceps brachii (caput lateralis)



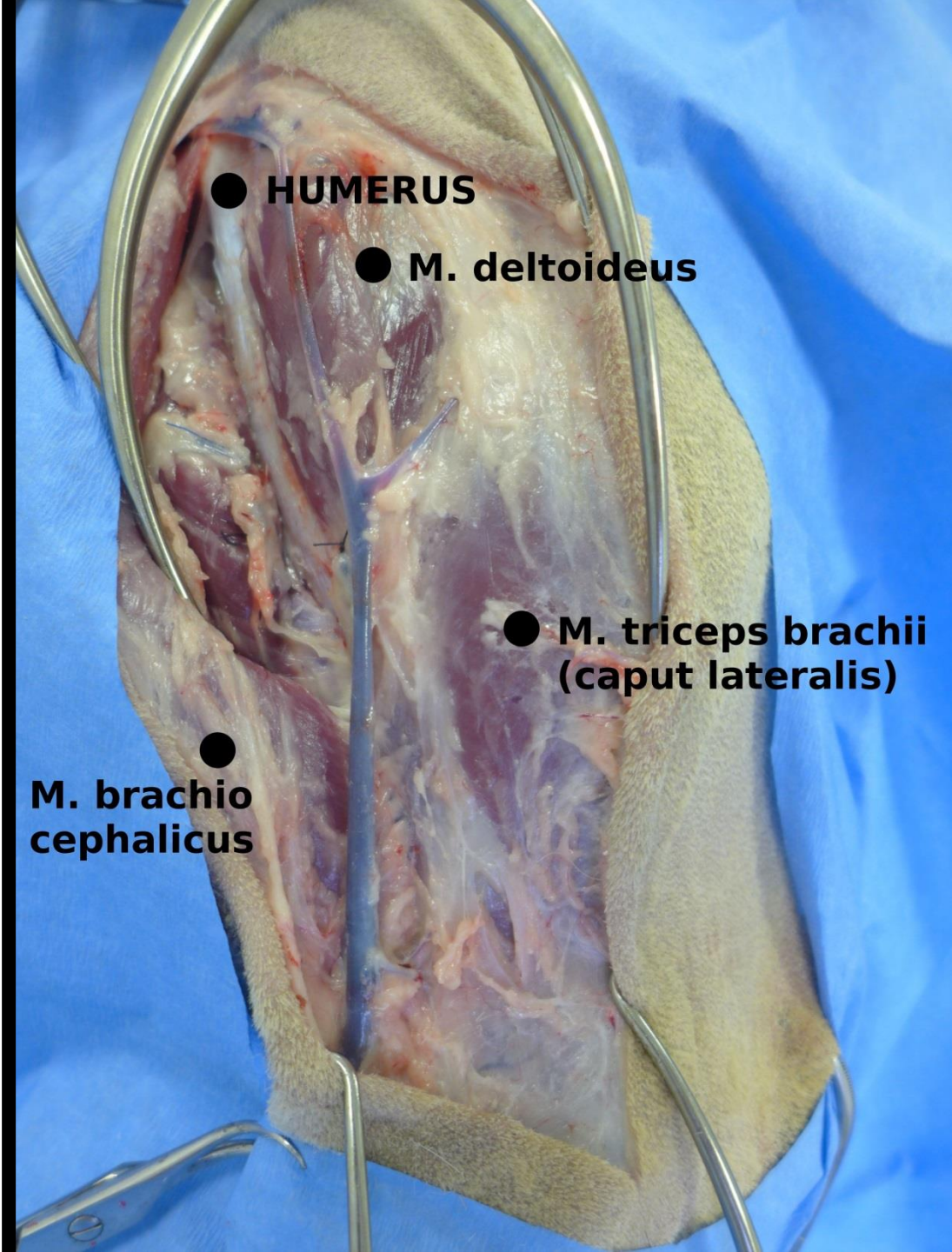
M. brachiocephalicus



M. deltoideus



V. cephalica

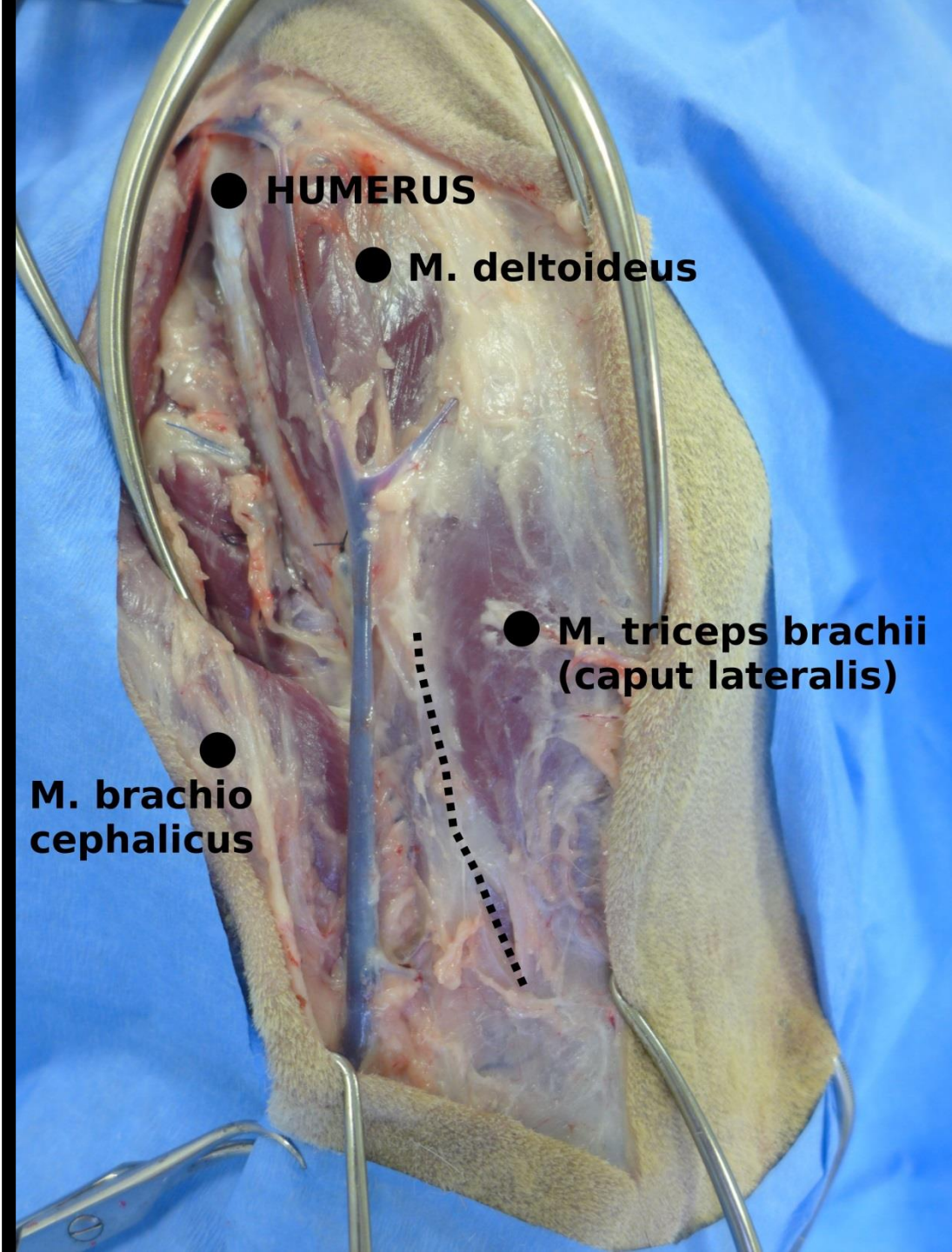


● HUMERUS

● M. deltoideus

● M. triceps brachii
(caput lateralis)

●
M. brachio
cephalicus

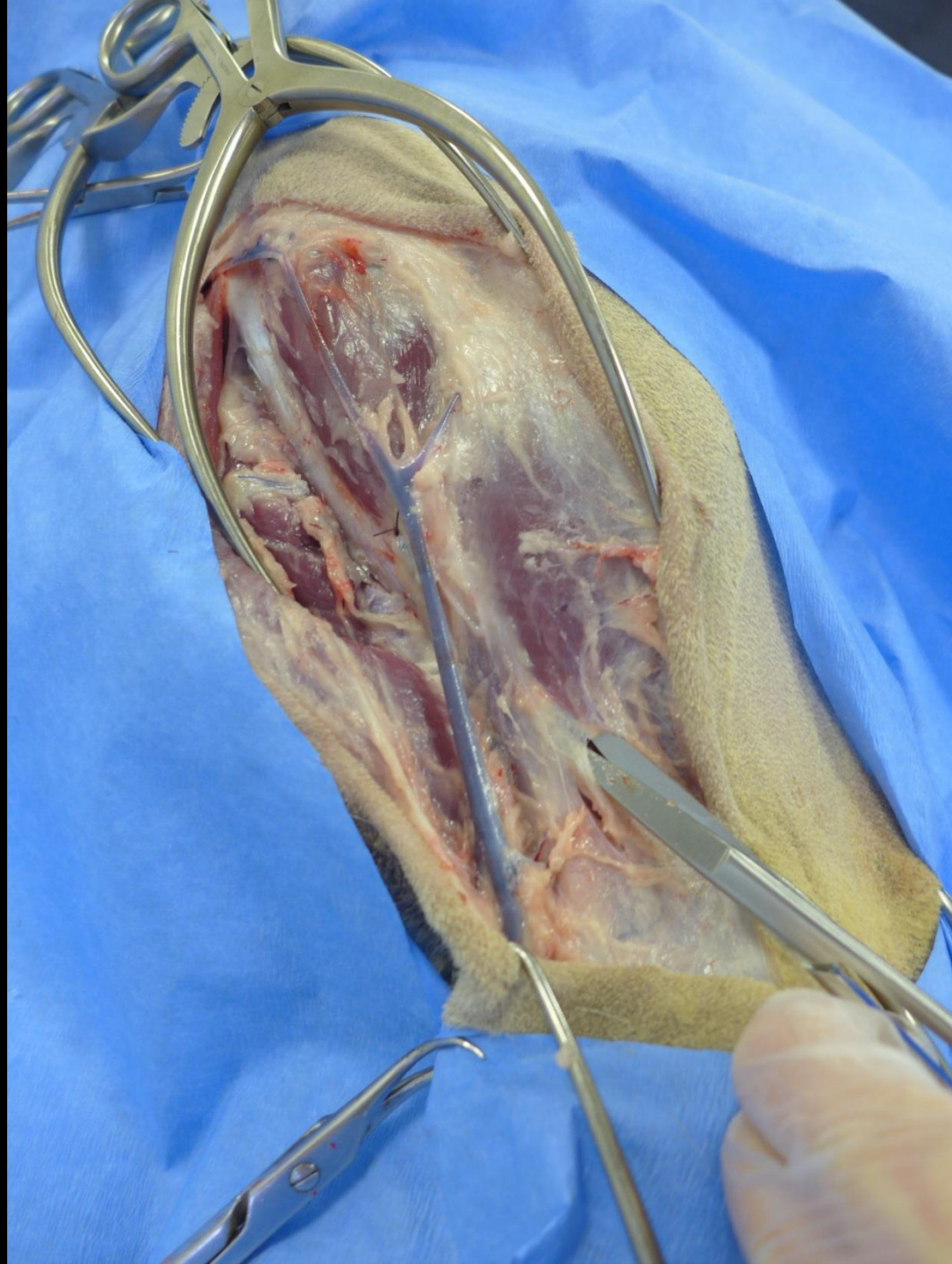

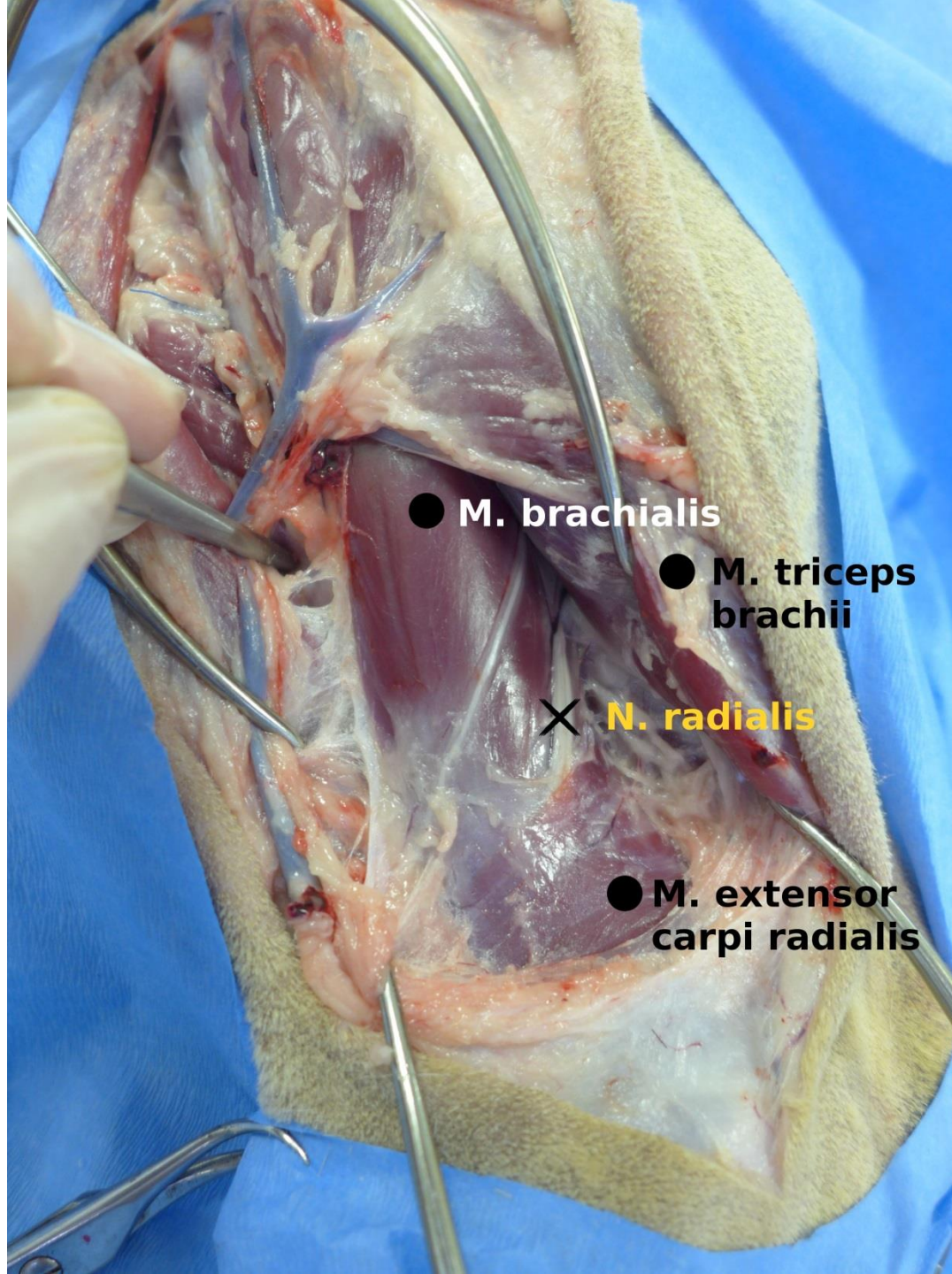
● HUMERUS

● M. deltoideus

● M. triceps brachii
(caput lateralis)

● M. brachio
cephalicus



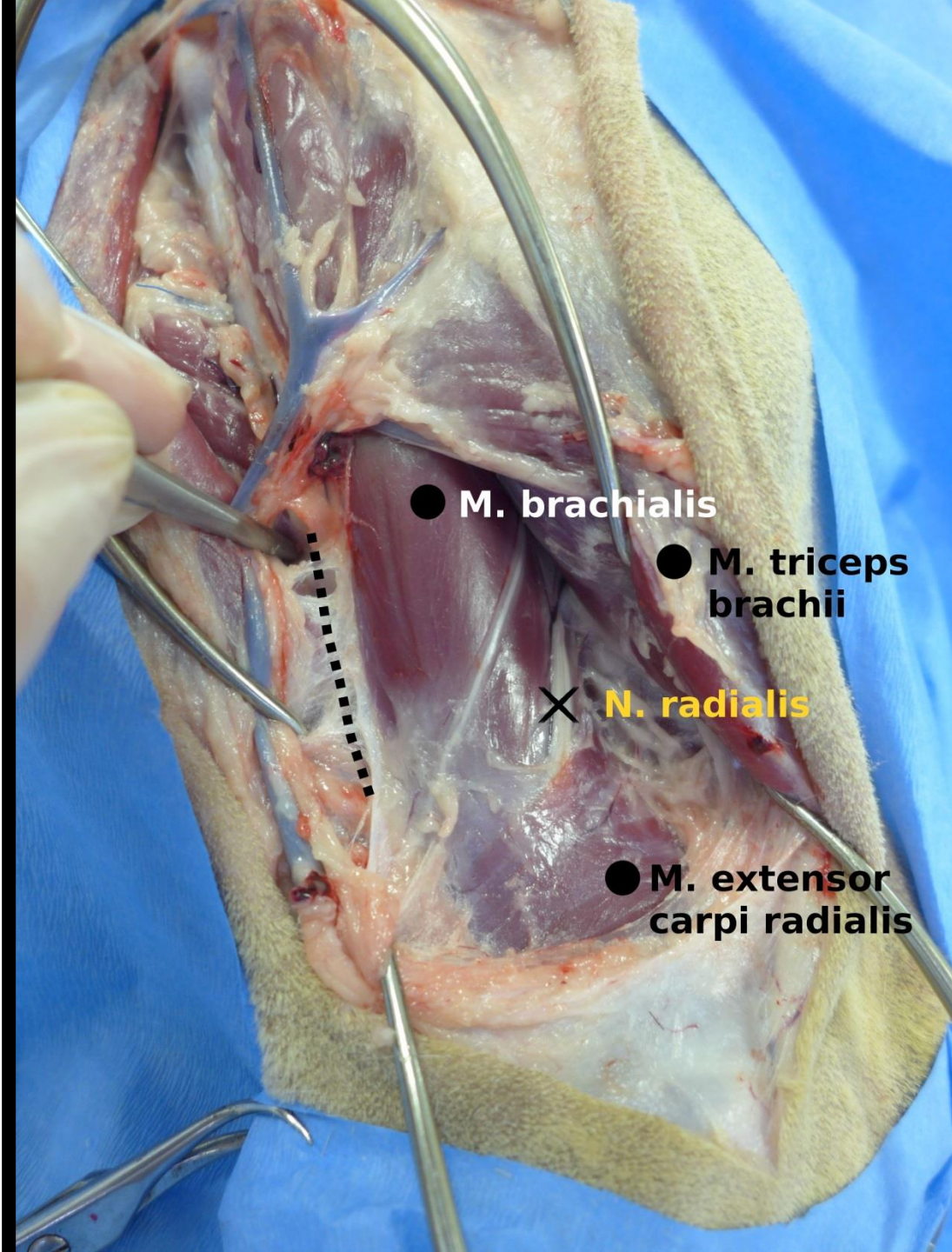


● M. brachialis

● M. triceps
brachii

× N. radialis

● M. extensor
carpi radialis



● M. brachialis

● M. triceps
brachii

× N. radialis

● M. extensor
carpi radialis

