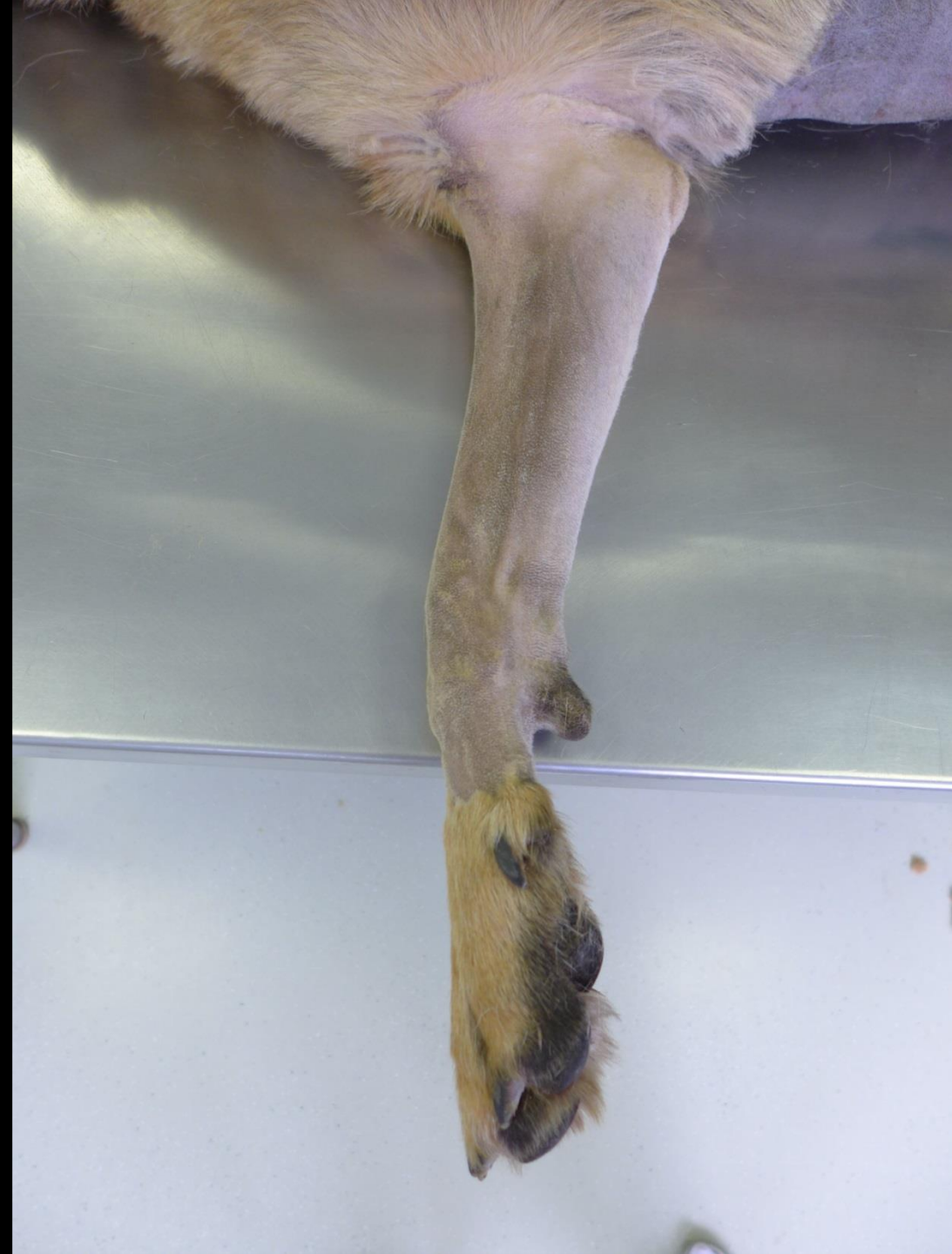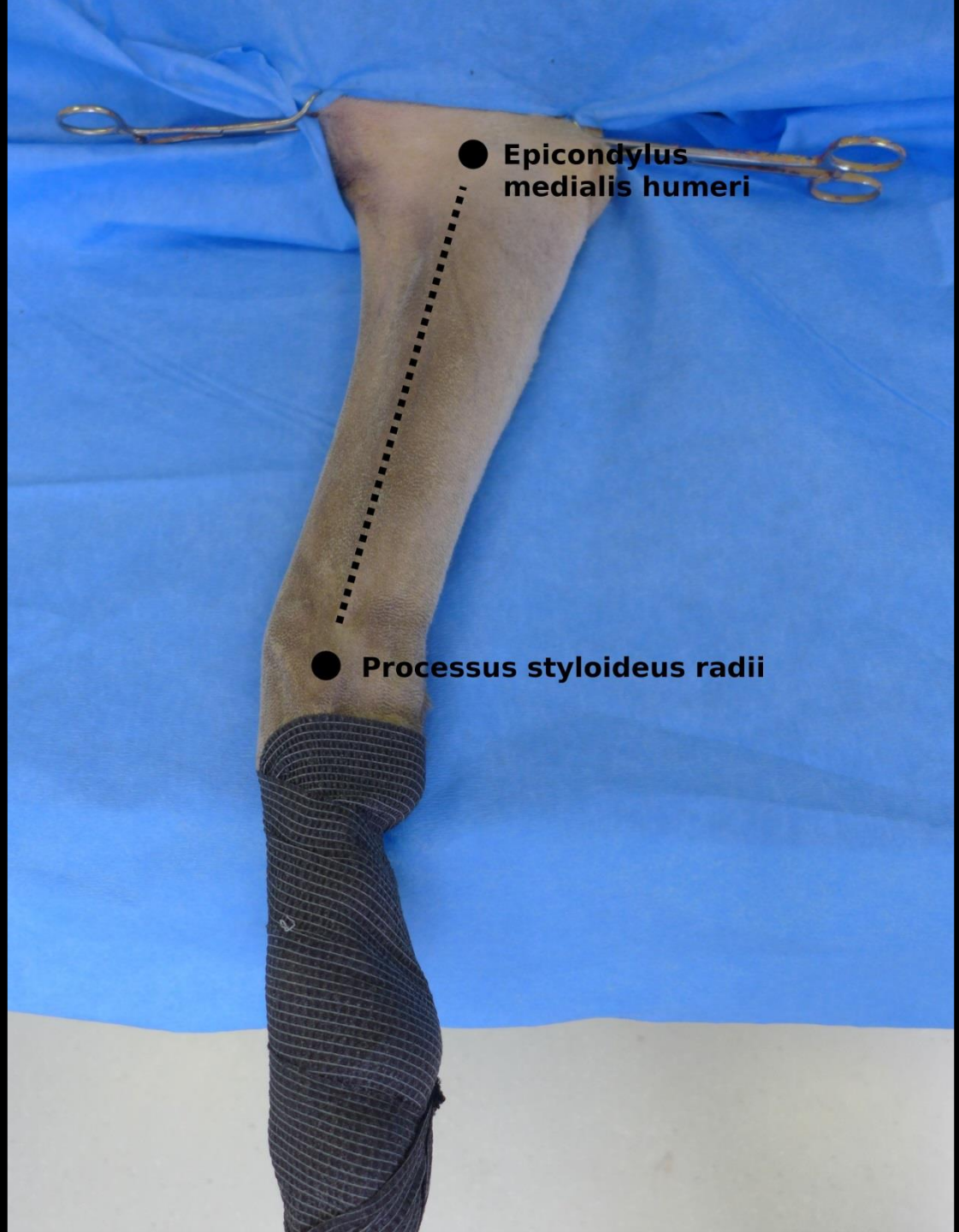


# Chirurgické přístupy ke kostem

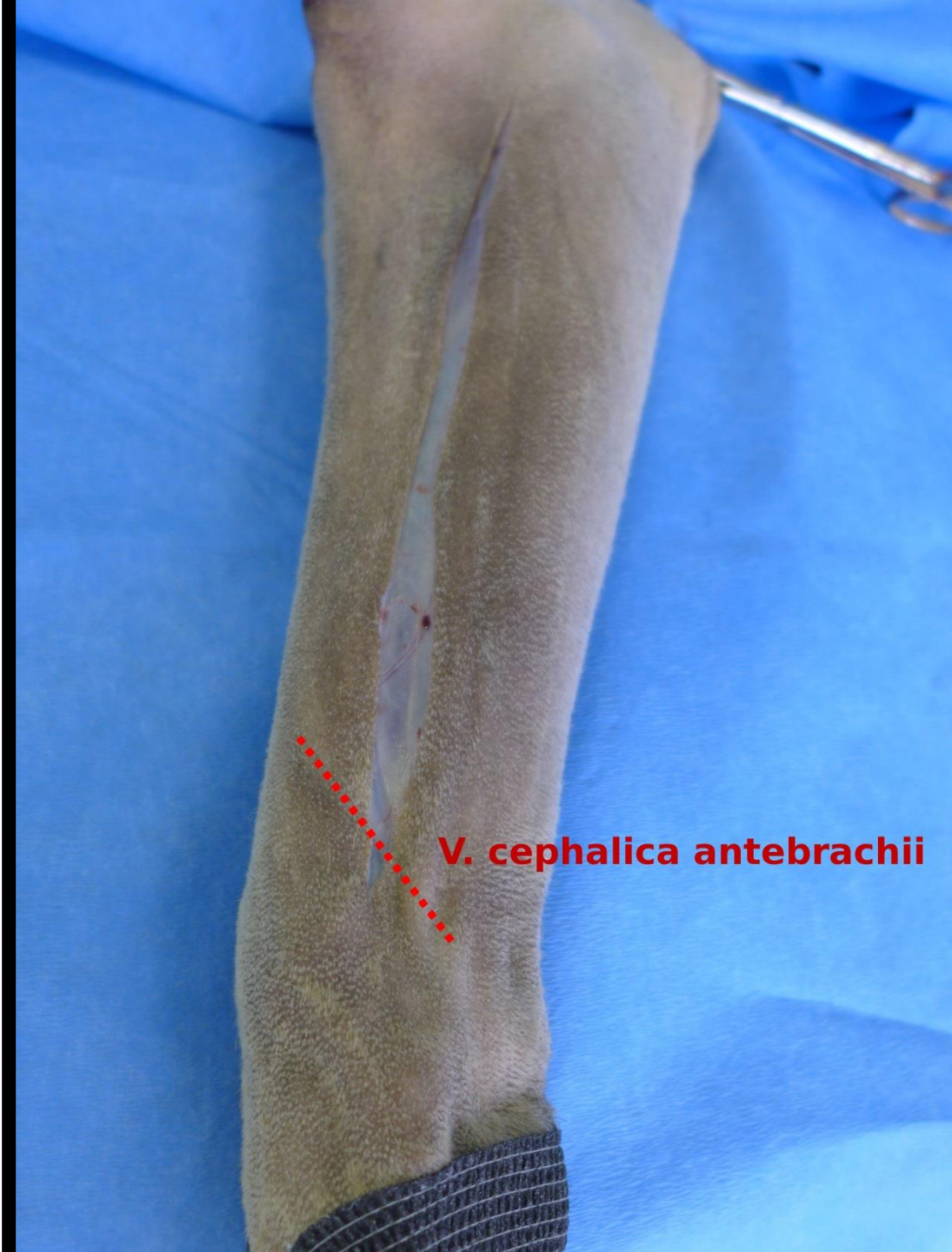Radius – mediální přístup





● **Epicondylus  
medialis humeri**

● **Processus styloideus radii**



**V. cephalica antebrachii**



M. extensor  
carpi radialis

● M. pronator teres



● Art. et nervus medianus

● M. flexor carpi radialis

● V. cephalica antebrachii



M. extensor  
carpi radialis

● M. pronator teres

● Art. et nervus medianus

● M. flexor carpi radialis

● V. cephalica antebrachii



M. extensor  
carpi radialis

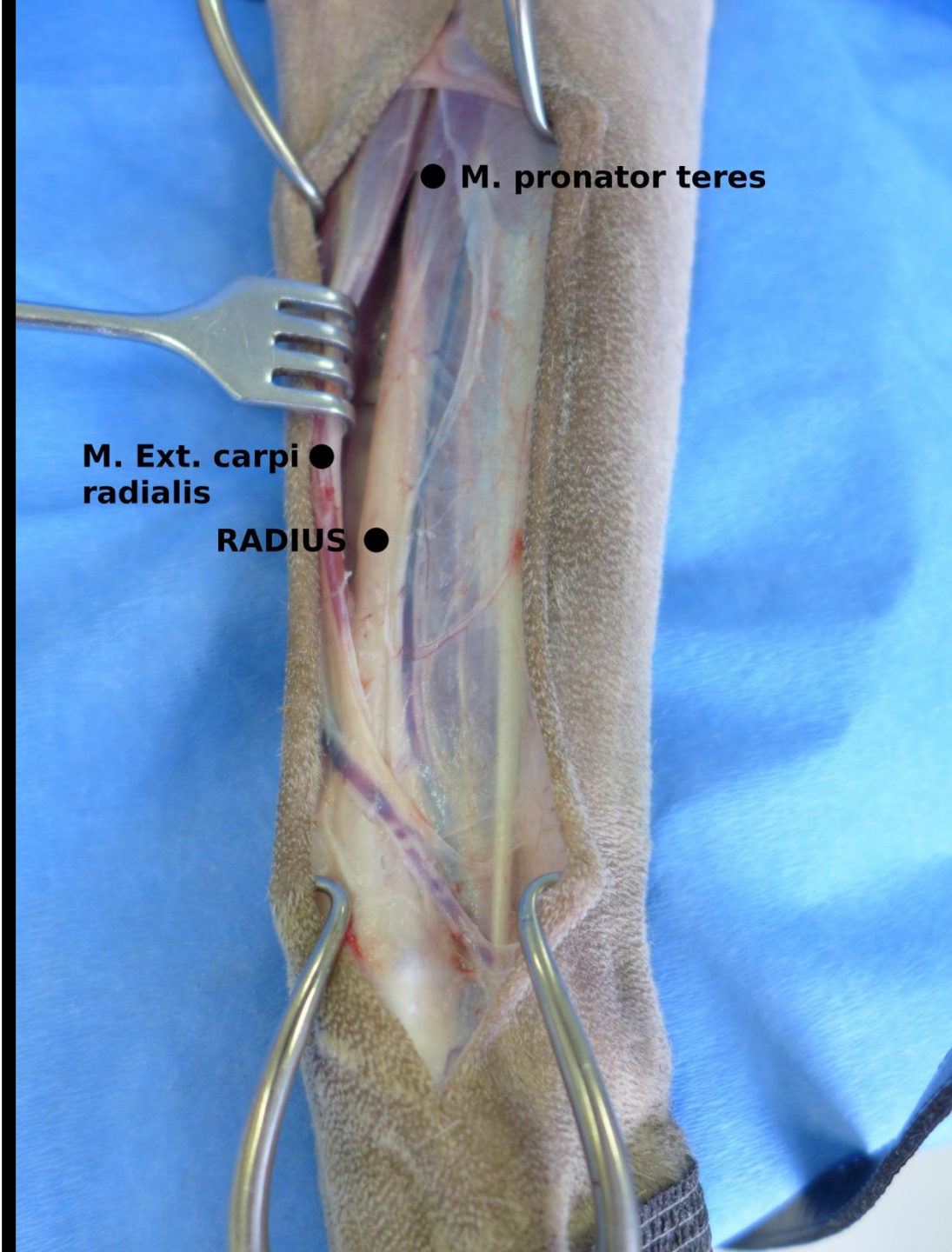
● M. pronator teres

Fascia antebrachii

● Art. et nervus medianus

● M. flexor carpi radialis

● V. cephalica antebrachii

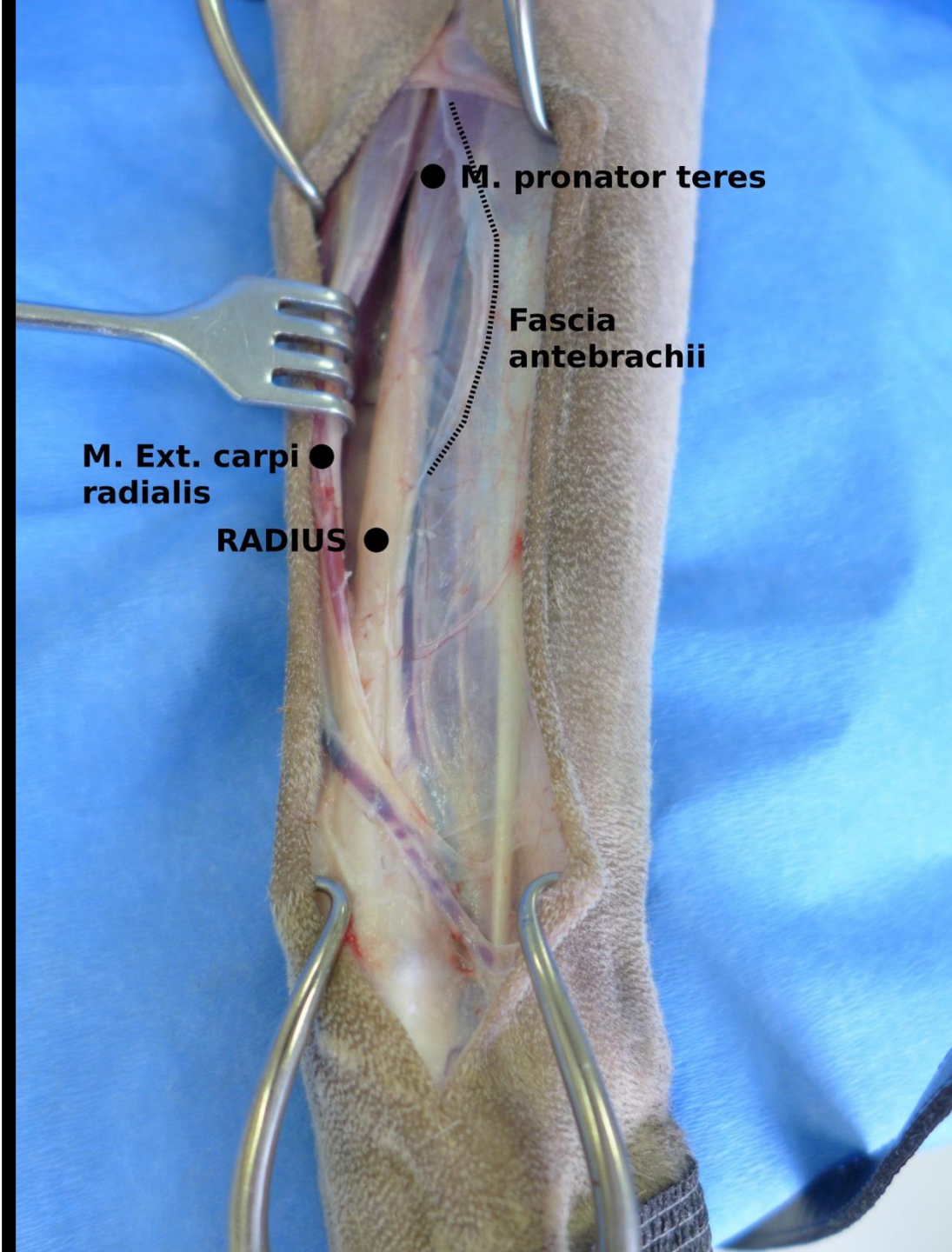


● M. pronator teres

M. Ext. carpi ●  
radialis

RADIUS ●



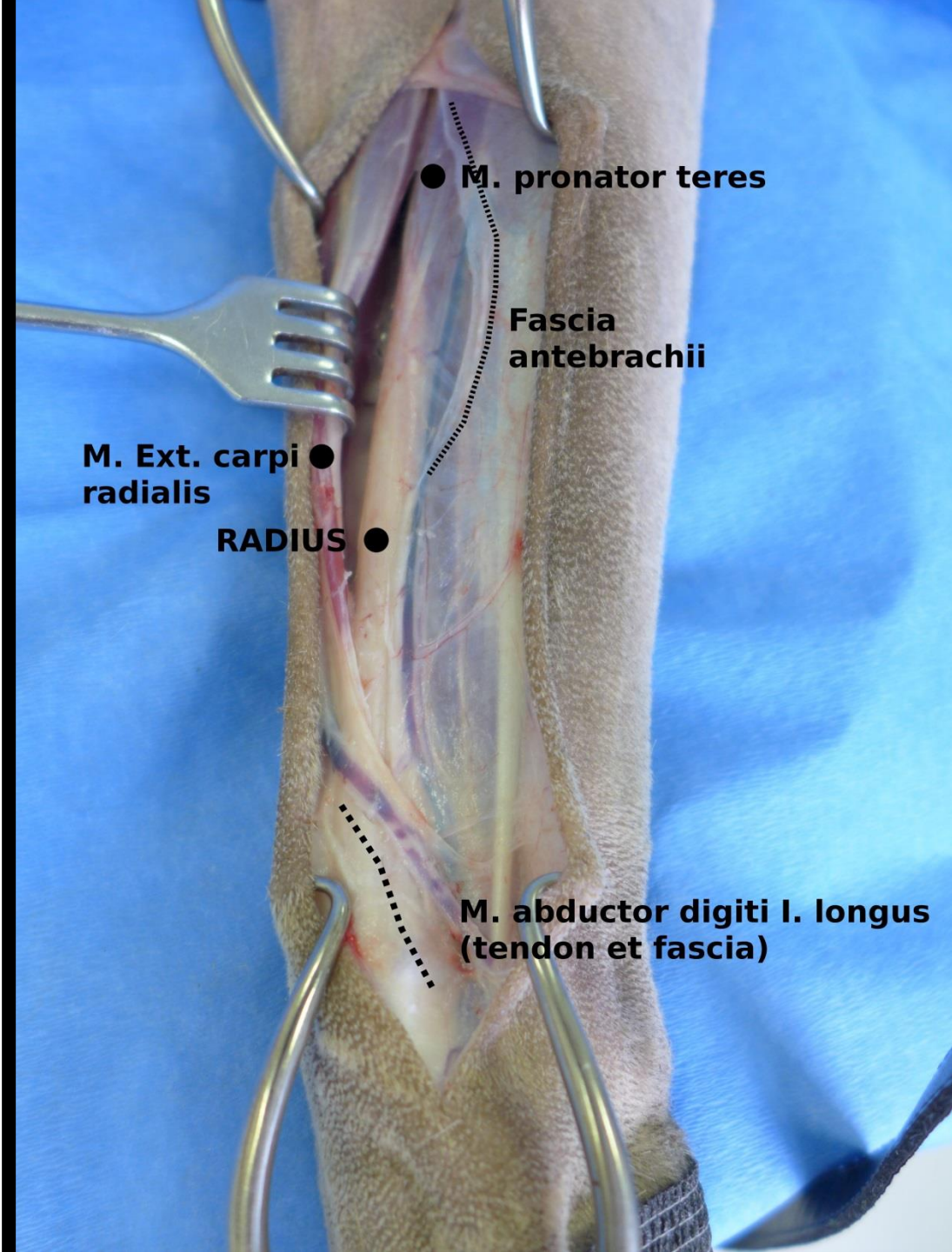


● M. pronator teres

Fascia  
antebrachii

M. Ext. carpi ●  
radialis

RADIUS ●



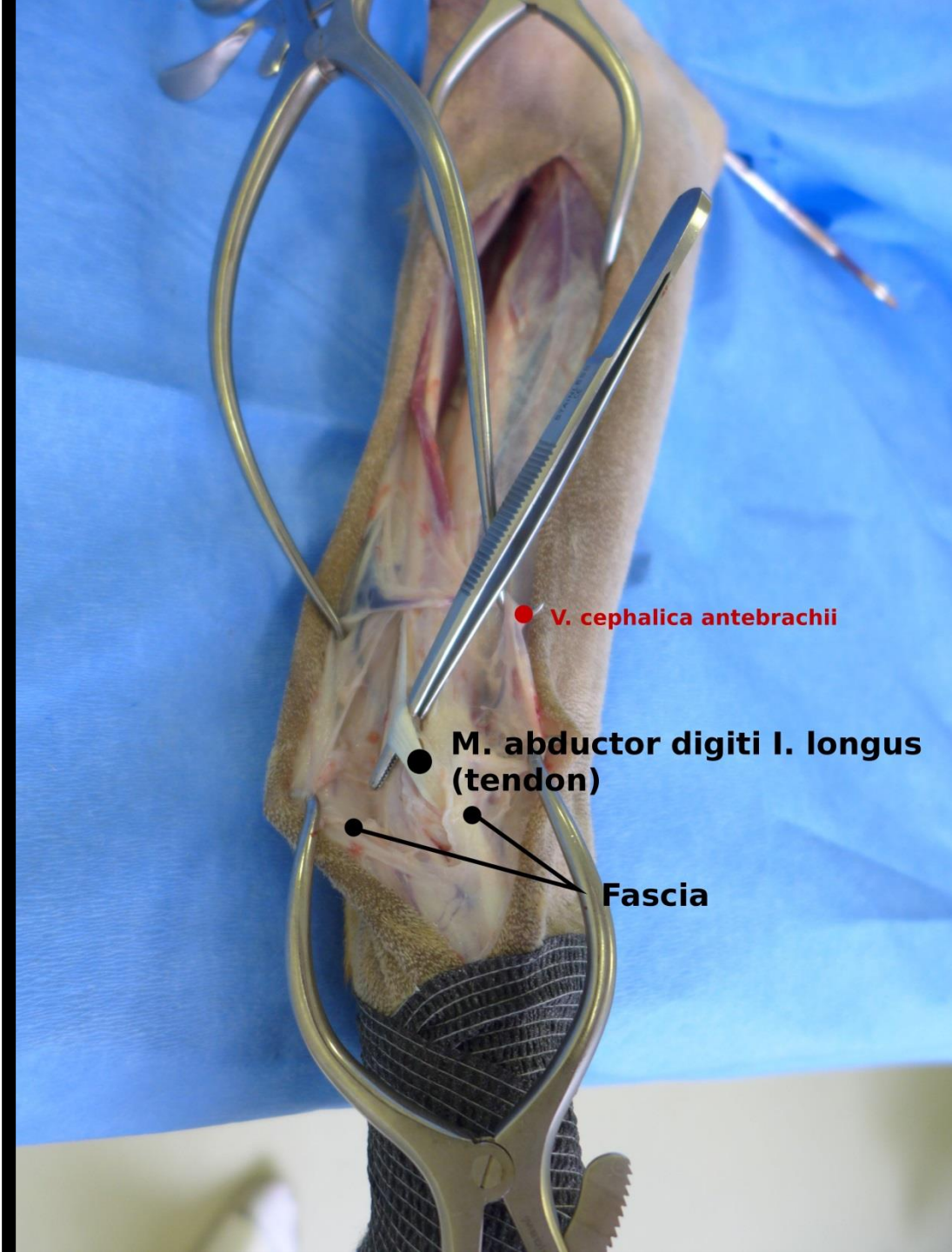● M. pronator teres

Fascia  
antebrachii

M. Ext. carpi ●  
radialis

RADIUS ●

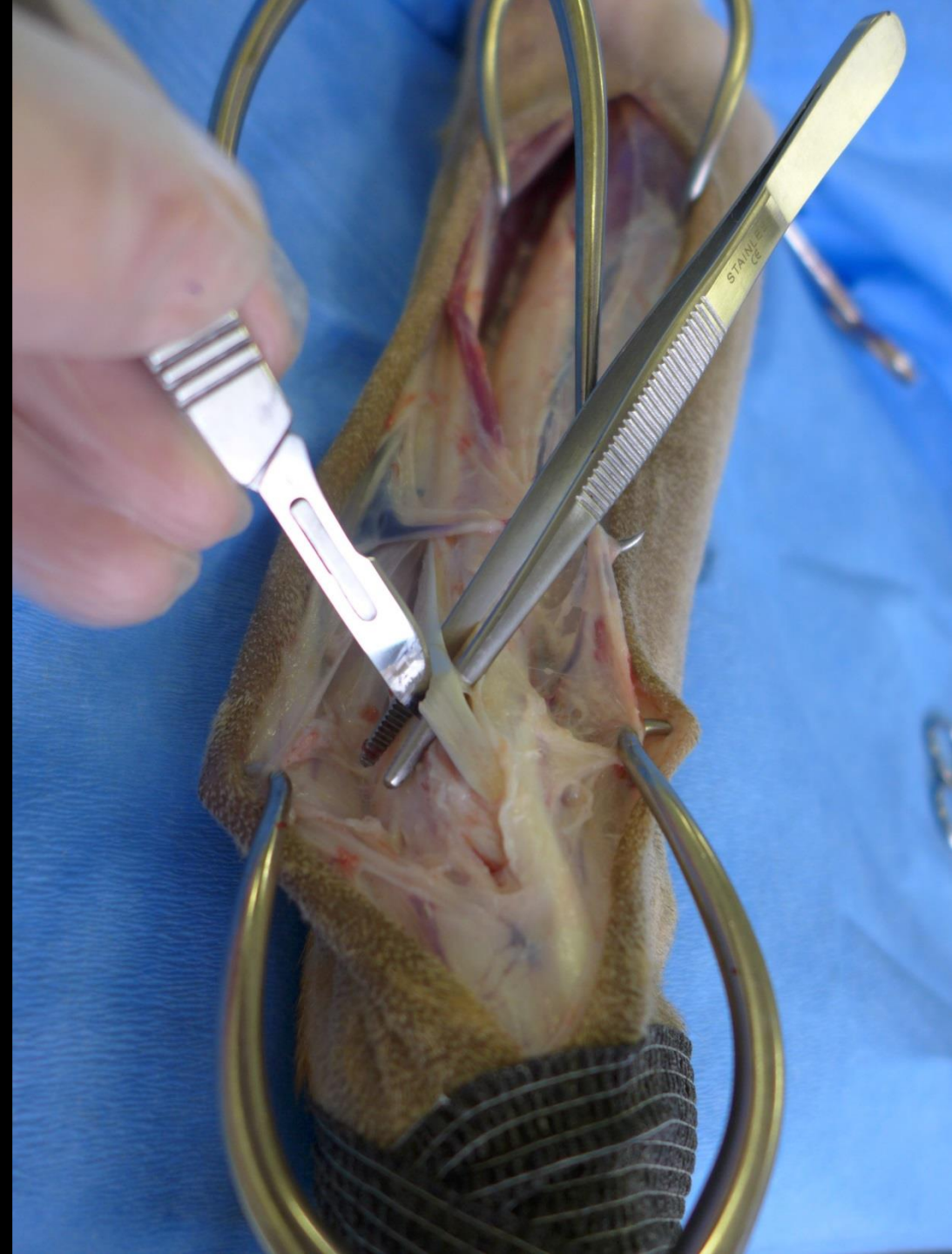
M. abductor digiti I. longus  
(tendon et fascia)

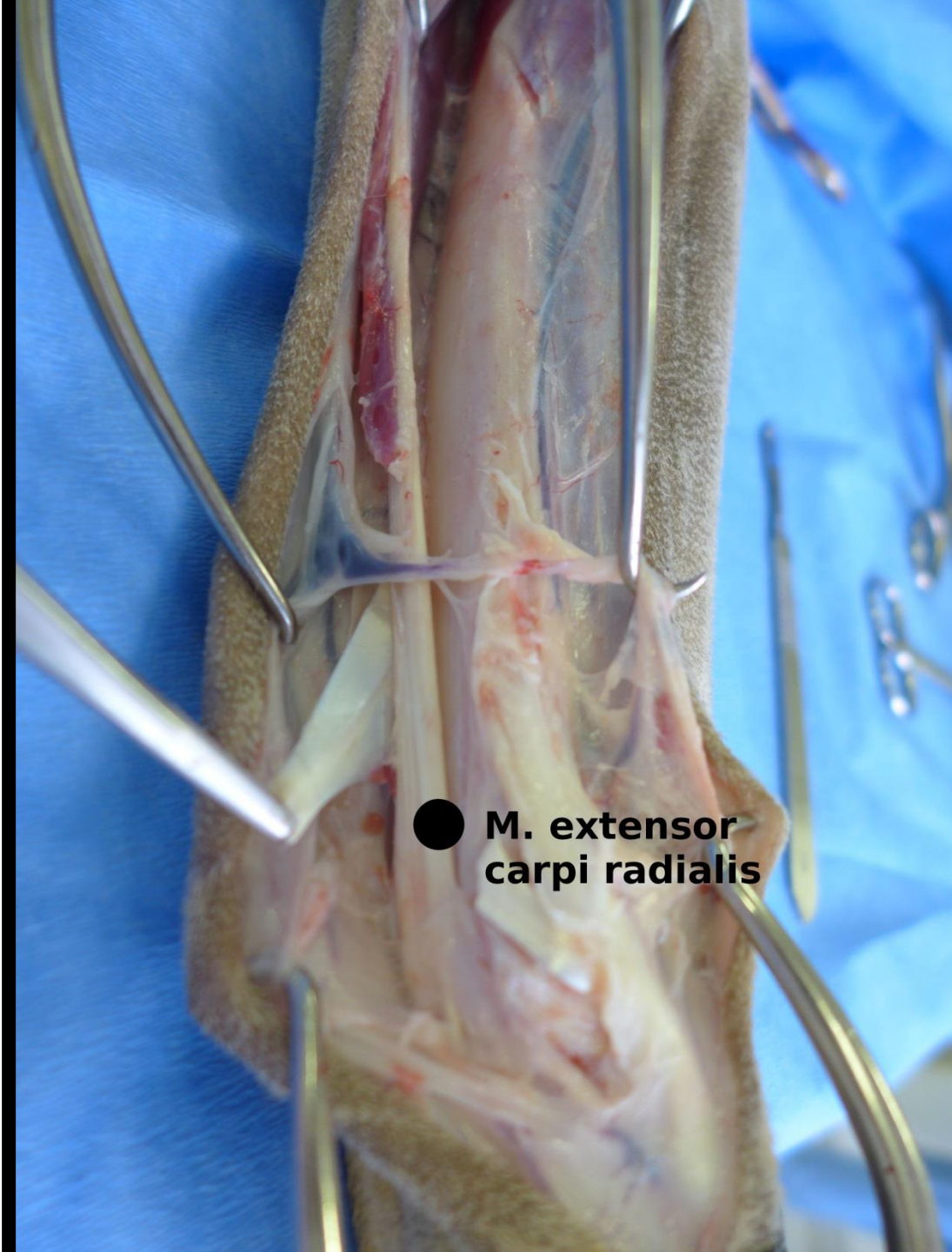


● **V. cephalica antebrachii**

● **M. abductor digiti I. longus (tendon)**

● **Fascia**





● **M. extensor  
carpi radialis**

